

Retrosplenial cortex (BA 29) volumes in behavioral variant frontotemporal dementia and Alzheimer's disease

Author:

Tan, Rachel; Wong, Stephanie; Hodges, John R; Halliday, Glenda; Hornberger, Michael

Publication details:

Dementia and Geriatric Cognitive Disorders
v. 35
Chapter No. 3-4
pp. 177-182
1420-8008 (ISSN)

Publication Date:

2013

Publisher DOI:

<http://dx.doi.org/10.1159/000346392>

License:

<https://creativecommons.org/licenses/by-nc-nd/3.0/au/>

Link to license to see what you are allowed to do with this resource.

Downloaded from <http://hdl.handle.net/1959.4/53598> in <https://unsworks.unsw.edu.au> on 2024-04-17

Title: Retrosplenial cortex (BA 29) volumes in behavioral variant frontotemporal dementia and Alzheimer's disease

Authors: Rachel H. Tan, PhD ^a, Stephanie Wong, BPsych (Hons) ^a, John R. Hodges, MD, FRCP ^{a,b,c}, Glenda M. Halliday, PhD^{a,b,c}, Michael Hornberger, PhD ^{a,b,c}

Authors' affiliation:

^a *Neuroscience Research Australia, Barker Street, Randwick, Sydney, 2031, Australia*

^b *School of Medical Sciences, University of New South Wales, Sydney, Australia*

^c *ARC Centre of Excellence in Cognition and its Disorders, Sydney, Australia*

Corresponding author:

Dr Michael Hornberger

Neuroscience Research Australia,

PO Box 1165

Sydney, Australia

Tel. +61 (02) 9399 1816

Email: m.hornberger@neura.edu.au

Running title: Retrosplenial cortex in bvFTD and AD

Keywords: Retrosplenial cortex, BA29, volumetric tracing, behavioral variant frontotemporal dementia, Alzheimer's disease

Pages: 11

Tables: 1

Figures: 2

Words: 1552

Abstract

Background. The retrosplenial cortex (RSC) is a crucial transit region between the hippocampus and cingulate cortex and has been implicated in spatial navigation and memory. Importantly, RSC atrophy is a predilection site of Alzheimer's (AD) pathology but there have been no studies assessing structural changes in the RSC in behavioral variant frontotemporal dementia (bvFTD).

Methods. A manual tracing method was used to calculate regional RSC volume in MRI scans from patients with bvFTD (n= 15) and AD (n= 15), as well as age and sex matched controls (n=15).

Results. RSC volumes were significantly reduced in the AD ($p<0.001$), but not the bvFTD cohort ($p>0.1$) compared to age-matched controls. RSC volumes discriminated bvFTD from AD in over 90% of the cases.

Conclusion. These findings provide further evidence that RSC atrophy is specific to AD, which might explain the commonly observed spatial disorientation in this patient group.

Introduction

The retrosplenial cortex (RSC) has been identified as a crucial transition region between the posterior cingulate cortex and posterior hippocampus (HC). The RSC is known to have strong reciprocal afferent and efferent connections with the HC and has therefore been implicated in spatial orientation and memory functions, although its specific function is still disputed [1, 2]. More recently, neurodegenerative changes in the RSC, such as hypometabolism and atrophy, have also been identified in early Alzheimer's disease (AD) [3, 4]. It has been known for a long time that AD patients show severe deficits in episodic memory as well as spatial disorientation [5, 6]. These deficits have been usually attributed to the well-documented HC atrophy in this patient group. Increasing evidence, however, suggests that other neurodegenerative conditions that do not present with topographical disorientation, such as behavioral variant frontotemporal dementia (bvFTD), can show a similar level of HC atrophy [7-9]. More importantly, bvFTD patients can have similar episodic memory deficits to AD but show virtually no spatial disorientation [10]. This functional dissociation of memory vs. spatial orientation across the two patient groups suggests there is a structural dissociation as well, with the HC more involved in memory processing and the RSC more involved in spatial orientation processing. This notion is corroborated by the findings of a recent VBM study [11], which demonstrated an association between the anterior hippocampus with memory performance in AD and bvFTD patients, and between the posterior hippocampus, at the level of transition towards RSC, with orientation in AD. However, VBM did not allow to measure the RSC itself, due to a lack of spatial resolution. The current study addresses this shortcoming, by employing manual tracing as a volumetric technique, to elucidate the relationship of HC and RSC volumes in bvFTD, AD and age-matched controls in more detail.

Methods

All patients were recruited with Ethics Committee approval and provided informed consent. Based on current diagnostic criteria, 45 participants (15 bvFTD, 15 AD and 15 cognitively healthy) were recruited. Clinical, neuropsychological and demographic data (Table 1) as well as 1mm isotropic voxel coronal MRI brain images were available for all cases. HC volumes were analyzed using a voxel-based morphometry (VBM) analysis as described elsewhere [12, 13]. Given the small size of the RSC, manual segmentation and volumetric analysis was performed in sequential coronal images at x9 magnification using the ImageJ software (version 1.44o; <http://imagej.nih.gov/ij/>). RSC borders were based on established methods [14] (*refer below*) and volumes were normalized to total brain volume. All measurements were performed while blinded to subject details and clinical diagnosis. Two independent raters were initially trained to identify the same regions of interest (ROI) in MRI images of control brains with less than 5% variation. The raters identified the ROI in 10 repeated measures of the ROI in 4 control cases with less than 5% variation, and a correlation of 0.953 between counts. Intra-rater scores had less than 2% variation.

Retrosplenial cortex borders. The retrosplenial cortex is comprised of a granular (BA 26/29) and agranular (BA 30) region located around the splenium of the corpus callosum [14]. The granular RSC was the region of interest in this study since recent evidence demonstrates it is the major target of cortical afferents to the RSC from the hippocampus [1]. The rostral border was defined as the most rostral coronal slice intersecting the head of the splenium of the corpus callosum (Figure 2A). In coronal slices, the medial border was defined by a 45° line drawn at the transition from granular to agranular cingulate cortex. The RSC continues to the isthmus of the cingulate gyrus, where the medial splitting of the corpus callosum in posterior coronal slices indicates the caudal limit of the RSC (Figure 2B). In slices immediately posterior to the medial split, the RSC appeared as an ‘island’ of grey matter medial to the fibres of the splenium (Figure 2B).

Statistical analysis. Data were analysed using SPSS19.0 (SPSS Inc., Chicago, IL). Parametric demographic (age, gender) and neuropsychological (memory and general cognitive tests) were compared across the 3 groups via analysis of variance (ANOVA) followed by Bonferroni's post hoc tests. Prior to these analyses, variables were plotted and checked for normality of distribution by Kolmogorov-Smirnov tests. Normalized RSC and HC volumes were expressed as a percentage of mean controls and compared across the three groups via ANOVAs with gender, age and CDR scores as covariates, followed by Bonferroni's post-hoc test. The degree of correlation between atrophic regional volumes in patients was assessed using Pearson's produce-moment correlation coefficients. For detailed description of the RSC borders, see detailed methods below.

Results

Demographics and general cognitive scores for the clinical cohort can be seen in Table 1. Comparisons of bvFTD vs AD cases revealed no significant difference in demographic variables. Control and patient groups were not significantly different for age but there were significantly more males in the bvFTD ($p < 0.05$) and AD ($p < 0.005$) cohorts compared to controls. The patient groups did not differ on the Clinical Dementia Rating (CDR) score ($p > 0.1$), indicating no difference in disease severity. On cognitive testing, the clinical patient groups differed significantly on the general cognitive measure (ACE-R) from controls ($p < 0.001$) but not from each other ($p > 0.1$).

Figure 1 shows that HC volumes were significantly reduced in both bvFTD and AD cohorts in comparison to controls ($p < 0.001$), whereas RSC volumes were significantly reduced only in the AD ($p < 0.001$) and not the bvFTD ($p > 0.1$) cohort. No significant correlation was found between the degree of atrophy in the HC and RSC in AD ($r = 0.26$; $p = 0.34$). A binary logistic regression using the Enter method with RSC volumes and patient groups (AD, bvFTD) as factors revealed that 93.3% of patients could be distinguished on their RSC volumes alone.

Discussion

Our findings demonstrate relative preservation of the RSC in bvFTD and confirm previous RSC atrophy findings in AD, extending this to include the caudal RSC region [4]. HC volumes were significantly reduced in both dementia groups, consistent with recent findings that have highlighted overlapping atrophy patterns of the HC in AD and bvFTD.

Navigational deficits are frequently observed with damage to the RSC in both humans and animals [2]. While human functional MRI studies have found both the RSC and HC are involved in the formation and use of cognitive maps, it is not fully understood if these two brain regions play complimentary roles or have dissociable contributions [15, 16]. Non-patient based studies have demonstrated these roles to be distinct but complimentary in long-term object recognition memory [9] and context appropriate memories and behaviors [17]. HC involvement in mediating RSC contributions to navigation was also demonstrated with observations of altered neuron activity in the RSC upon HC inactivation in rats during a spatial navigation task [18].

Bird and colleagues (2010) recently demonstrated that patients with AD, but not bvFTD, were impaired on topographical short-term memory and suggested damage to the RSC in AD may be responsible for this. The results of the present study provide support for this concept [8] and suggest that performance on spatial orientation is more likely to be contingent upon the preservation of the RSC. This may further explain the commonly seen spatial disorientation in AD while bvFTD patients are usually well orientated in space and time, despite both conditions having significant HC damage.

One important difference to previous studies was that the current study employed a manual volumetric protocol which focused solely on the measurement of Brodmann area (BA) 29 of the RSC, which is the main target of HC projections to the RSC [1]. Previous RSC volume measurements [4] have included BA 30, which predominantly receives inputs from the

dorsolateral prefrontal, parietal and visual cortex, and less commonly from the subiculum [1, 14]. Given the larger size of the isocortical BA 30, inclusion of this region may overshadow volume changes in the adjacent allocortical BA 29 region and hinder significance of results. Thus, our methods have allowed a more focused investigation of related HC-RSC brain regions.

Interestingly, we found no significant correlation between the degree of atrophy in the HC and RSC in AD, suggesting that these two brain regions do not degenerate simultaneously. This is in line with previous findings showing that prodromal AD patients already show posterior cingulate/RSC atrophy while the HC is less affected [3]. Overall, these results suggest that HC and RSC regions have dissociable functions with the latter being more involved in spatial orientation. In future studies it would be important to show this by contrasting HC and RSC volumes with episodic and topographical memory performance in the same patients directly, to further substantiate the claim that the HC and RSC have dissociable functions.

Conflict of interest statement

None

Acknowledgements

This study was funded by the National Health and Medical Research Council of Australia and the Australian Research Council.

References

1. Aggleton, J.P., N.F. Wright, S.D. Vann, and R.C. Saunders, *Medial temporal lobe projections to the retrosplenial cortex of the macaque monkey*. Hippocampus, 2012.
2. Vann, S.D., J.P. Aggleton, and E.A. Maguire, *What does the retrosplenial cortex do?* Nat Rev Neurosci, 2009. **10**(11): p. 792-802.
3. Nestor, P.J., T.D. Fryer, M. Ikeda, and J.R. Hodges, *Retrosplenial cortex (BA 29/30) hypometabolism in mild cognitive impairment (prodromal Alzheimer's disease)*. Eur J Neurosci, 2003. **18**(9): p. 2663-7.
4. Pengas, G., J.R. Hodges, P. Watson, and P.J. Nestor, *Focal posterior cingulate atrophy in incipient Alzheimer's disease*. Neurobiol Aging, 2010. **31**(1): p. 25-33.
5. Chiu, Y.C., D. Algate, A. Whall, J. Liang, H.C. Liu, K.N. Lin, and P.N. Wang, *Getting lost: directed attention and executive functions in early Alzheimer's disease patients*. Dement Geriatr Cogn Disord, 2004. **17**(3): p. 174-80.
6. Le Moal, S., J.M. Reymann, V. Thomas, C. Cattenoz, A. Lieury, and H. Allain, *Effect of normal aging and of Alzheimer's disease on, episodic memory*. Dement Geriatr Cogn Disord, 1997. **8**(5): p. 281-7.
7. van de Pol, L.A., A. Hensel, W.M. van der Flier, P.J. Visser, Y.A. Pijnenburg, F. Barkhof, H.J. Gertz, and P. Scheltens, *Hippocampal atrophy on MRI in frontotemporal lobar degeneration and Alzheimer's disease*. J Neurol Neurosurg Psychiatry, 2006. **77**(4): p. 439-42.
8. Bird, C.M., D. Chan, T. Hartley, Y.A. Pijnenburg, M.N. Rossor, and N. Burgess, *Topographical short-term memory differentiates Alzheimer's disease from frontotemporal lobar degeneration*. Hippocampus, 2010. **20**(10): p. 1154-69.
9. Haijima, A. and Y. Ichitani, *Dissociable anterograde amnesic effects of retrosplenial cortex and hippocampal lesions on spontaneous object recognition memory in rats*. Hippocampus, 2012.
10. Hornberger, M., O. Piguet, A.J. Graham, P.J. Nestor, and J.R. Hodges, *How preserved is episodic memory in behavioral variant frontotemporal dementia?* Neurology, 2010. **74**(6): p. 472-9.
11. Yew, B., S. Alladi, M. Shailaja, J.R. Hodges, and M. Hornberger, *Lost and Forgotten? Orientation versus Memory in Alzheimer's Disease and Frontotemporal Dementia*. J Alzheimers Dis, 2012.
12. Hornberger, M., S. Wong, R. Tan, M. Irish, O. Piguet, J. Kril, J.R. Hodges, and G. Halliday, *In vivo and post-mortem memory circuit integrity in frontotemporal dementia and Alzheimer's disease*. Brain, 2012. **135**(Pt 10): p. 3015-25.
13. Ashburner, J. and K.J. Friston, *Voxel-based morphometry--the methods*. Neuroimage, 2000. **11**(6 Pt 1): p. 805-21.

14. Paxinos, G., *The Human nervous system* 1990, San Diego: Academic Press. xi, 1195 p.
15. Iaria, G., J.K. Chen, C. Guariglia, A. Ptito, and M. Petrides, *Retrosplenial and hippocampal brain regions in human navigation: complementary functional contributions to the formation and use of cognitive maps*. Eur J Neurosci, 2007. **25**(3): p. 890-9.
16. Wolbers, T. and C. Buchel, *Dissociable retrosplenial and hippocampal contributions to successful formation of survey representations*. J Neurosci, 2005. **25**(13): p. 3333-40.
17. Smith, D.M., J. Barredo, and S.J. Mizumori, *Complimentary roles of the hippocampus and retrosplenial cortex in behavioral context discrimination*. Hippocampus, 2012. **22**(5): p. 1121-33.
18. Kubik, S., T. Miyashita, A. Kubik-Zahorodna, and J.F. Guzowski, *Loss of activity-dependent Arc gene expression in the retrosplenial cortex after hippocampal inactivation: interaction in a higher-order memory circuit*. Neurobiol Learn Mem, 2012. **97**(1): p. 124-31.

Table 1. Patient demographics. Means (standard deviations)

	bvFTD	AD	Controls	F values	bvFTD vs AD	bvFTD vs controls	AD vs controls
N	15	15	15	-	-	-	-
Gender (M/F)	12/3	13/2	5/10	^d	NS	^d	^c
Age ± SD (yrs)	59.2 (7.4)	65 (8.4)	65 (8.2)	NS	-	-	-
CDR	1.1 (0.7)	0.9 (0.5)	-	NS	-	-	-
ACE-R (100)	76.6 (8.1)*	78.5 (11.9)*	96.3 (2.3)	^b	NS	^b	^b

Abbreviations: CDR = Clinical Dementia Rating; ACER = Addenbrooke's Cognitive Examination Revised; AD = Alzheimer disease; bvFTD = behavioral variant frontotemporal dementia; NS = non significant; ^aF values indicate significant differences across groups; Bonferonni's post hoc tests compare differences between group pairs. ^bp < 0.001; ^cp < 0.01; ^dp < 0.05.

Table 2. BA29 ROI volumes. Means (standard deviation)

	Left hemisphere	Right hemisphere	Sum of left and right hemispheres
Raw brain volumes (mm3)			
Control	105.0 (30.8)	97.0 (30.8)	202.0 (47.8)
AD	84.7 (24.8)	72.4 (24.8)	157.1 (34.1)
bvFTD	120.8 (43.1)	112.8 (43.1)	233.6 (76.1)
TBV corrected volumes as a % of control			
Control	100 (28.4)	100 (30.6)	100 (22.7)
AD	-25.0 (20.8)	-31.3 (22.3)	-28.0 (13.4)
bvFTD	12.9 (37.7)	14.0 (40.5)	13.0 (33.7)

ROI Region of interest; TBV Total brain volumes

Figure 1. Percentage atrophy of RSC and hippocampus in bvFTD and AD compared to controls. Box plot whiskers indicate minimum and maximum values. Scatter dot plots represent Mean \pm Standard deviation. Shaded areas represent standard deviation in controls. * $p < 0.05$, ** $p < 0.001$ different from controls.
178x145mm (300 x 300 DPI)

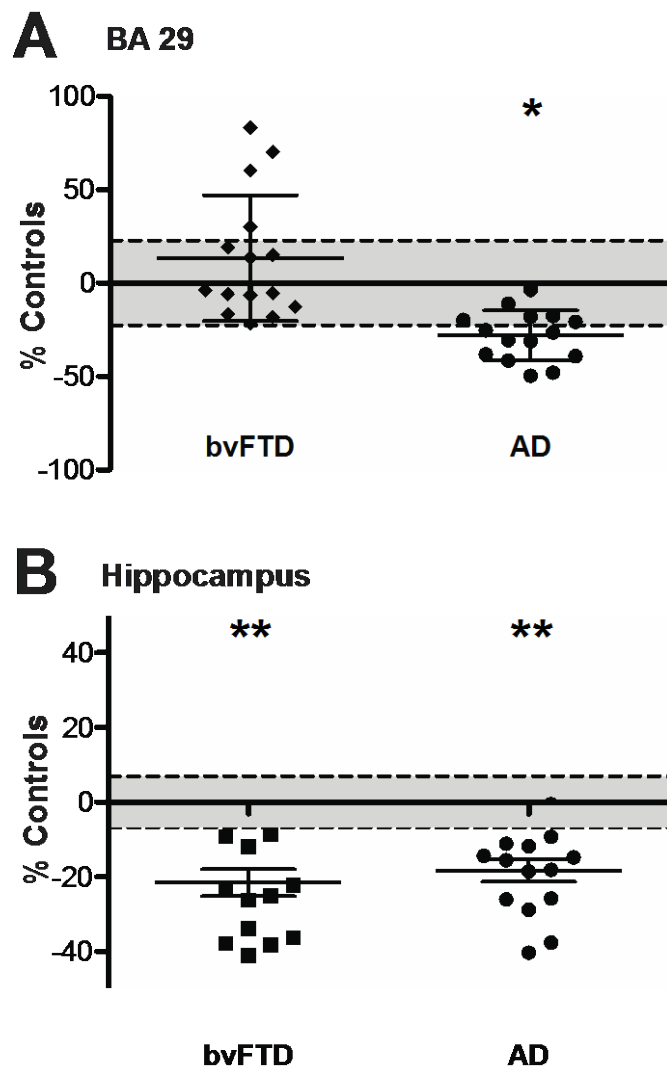


Figure 2. Retrosplenial cortex (RSC) borders. (A) Sagittal section of MRI scan (left hemisphere) delineating the RSC. (B) Coronal section of the rostral border demonstrating the granular RSC. (C) Posterior coronal section demonstrating the caudal end of the RSC. 175x71mm (300 x 300 DPI)

